



Research Techniques Made Simple: Animal Models of Wound Healing

Ayman Grada¹, Joshua Mervis² and Vincent Falanga¹

Animal models have been developed to study the complex cellular and biochemical processes of wound repair and to evaluate the efficacy and safety of potential therapeutic agents. Several factors can influence wound healing. These include aging, infection, medications, nutrition, obesity, diabetes, venous insufficiency, and peripheral arterial disease. Lack of optimal preclinical models that are capable of properly recapitulating human wounds remains a significant translational challenge. Animal models should strive for reproducibility, quantitative interpretation, clinical relevance, and successful translation into clinical use. In this concise review, we discuss animal models used in wound experiments including mouse, rat, rabbit, pig, and zebrafish, with a special emphasis on impaired wound healing models.

Journal of Investigative Dermatology (2018) **138**, 2095–2105; doi:10.1016/j.jid.2018.08.005

CME Activity Dates: 20 September 2018

Expiration Date: 19 September 2019

Estimated Time to Complete: 1 hour

Planning Committee/Speaker Disclosure: All authors, planning committee members, CME committee members and staff involved with this activity as content validation reviewers have no financial relationships with commercial interests to disclose relative to the content of this CME activity.

Commercial Support Acknowledgment: This CME activity is supported by an educational grant from Lilly USA, LLC.

Description: This article, designed for dermatologists, residents, fellows, and related healthcare providers, seeks to reduce the growing divide between dermatology clinical practice and the basic science/current research methodologies on which many diagnostic and therapeutic advances are built.

Objectives: At the conclusion of this activity, learners should be better able to:

- Recognize the newest techniques in biomedical research.
- Describe how these techniques can be utilized and their limitations.
- Describe the potential impact of these techniques.

CME Accreditation and Credit Designation: This activity has been planned and implemented in accordance with the accreditation requirements and policies of the Accreditation Council for Continuing Medical Education through the joint providership of Beaumont Health and the Society for Investigative Dermatology. Beaumont Health is accredited by the ACCME to provide continuing medical education for physicians. Beaumont Health designates this enduring material for a maximum of 1.0 *AMA PRA Category 1 Credit(s)*[™]. Physicians should claim only the credit commensurate with the extent of their participation in the activity.

Method of Physician Participation in Learning Process: The content can be read from the Journal of Investigative Dermatology website: <http://www.jidonline.org/current>. Tests for CME credits may only be submitted online at <https://beaumont.cloud-cme.com/RTMS-Oct18> — click 'CME on Demand' and locate the article to complete the test. Fax or other copies will not be accepted. To receive credits, learners must review the CME accreditation information; view the entire article, complete the post-test with a minimum performance level of 60%; and complete the online evaluation form in order to claim CME credit. The CME credit code for this activity is: 21310. For questions about CME credit email cme@beaumont.edu.

INTRODUCTION

The critical processes underlying wound healing have been initially described using animal models (Eming et al., 2014; Martin, 1997). Although animals do not develop chronic wounds in a way that closely resembles those arising in humans, animal models have provided valuable insights into the principles of wound management. For example, the now accepted notion that wounds heal faster when kept moist came from research experiments in the domestic pig (Helfman et al., 1994). However, because of anatomical

and physiological differences among and within animal species, including humans, no single model can suit all needs. Data generated from preclinical studies on wound repair may vary considerably depending on the animal model chosen and on other biological variables such as age, sex, microbiome, and wound location (Elliot et al., 2018). Preclinical models should be validated before proceeding with testing.

When looking at preclinical models of wound healing, the majority of studies are performed in either rodents or pigs.

¹Department of Dermatology, Boston University School of Medicine, Boston, Massachusetts, USA; and ²Boston University School of Medicine, Boston, Massachusetts, USA

Correspondence: Ayman Grada, Department of Dermatology, Boston University School of Medicine, 609 Albany Street, J313, Boston, Massachusetts 02118, USA. E-mail: Grada@bu.edu

BENEFITS

- Investigating mechanisms of wound repair and regeneration.
- Testing the efficacy and safety of potential therapeutics.
- Ethical regulations prohibit the use of humans, especially humans with impaired wound healing, in potentially harmful studies.

LIMITATIONS

- Anatomical and physiological differences among and within animal species, including humans. No one model can recapitulate the heterogeneity and complexity of chronic wounds in humans.
- Reproducibility and translation of preclinical data into clinical reality remains an ultimate challenge.
- Lack of standardization in designs and procedures.

Primates are rarely used, mainly because of the higher cost and animal care committees' concerns regarding these animals. Moreover, primates heal with far less collagen deposition than humans do. Other animals offer limited benefit for wound research because of their size, temperament, and maintenance expense.

ACUTE AND IMPAIRED HEALING

The natural (acute) wound healing process in adult mammals, including humans, progresses in four orderly phases that overlap in time: coagulation, inflammation, migration-proliferation (including matrix deposition), and remodeling (Falanga, 2005). Acute wounds, such as those created by surgery or trauma, occur suddenly and heal in a relatively predictable timeframe. Deregulation or interruption of one or more phases of the normal healing process leads to chronic wounds (Eming, 2014). A chronic wound is a wound that fails to progress through the normal phases of healing in an orderly and timely manner. Persistent inflammation is a hallmark of the chronic wound microenvironment. Some of the major causes of impaired wound healing include diabetes mellitus, vascular insufficiencies, and prolonged local pressure.

ANIMAL MODELS OF ACUTE HEALING

Acute wound models are useful for studying the natural healing processes and for drug discovery. Although we will focus mainly on models of impaired healing, acute wound models that are commonly used include excisional, incisional, and burn models, which all have well-established protocols (DiPietro and Burns, 2003).

ANIMAL MODELS OF IMPAIRED HEALING

Chronic wounds in animals can be created from an acute wound by inducing diabetes, mechanical pressure, ischemia, or reperfusion injury. Chronic wounds are uncommon in

animals, and thus all animal models have limitations (Mustoe et al., 2006).

Diabetic wound models

No single model can reproduce the entire diabetic pathological process and its variations. Each model mimics merely one aspect of this complex disease. Hyperglycemia can be chemically induced in mice and rats by intraperitoneal or caudal vein injection of streptozotocin or alloxan to cause selective destruction of insulin-producing beta cells of the pancreas. Animals are allowed to manifest hyperglycemia for several weeks before making a cutaneous wound through cutting, burning, or radiation. A pig model of diabetic ulcers was established (Velandar et al., 2008). However, these wounds healed after 18 days, which is not consistent with diabetic wounds in humans. Diabetes and insulin resistance can be induced by genetic manipulation as well. There are two types: type 1 diabetes models include the nonobese diabetic (i.e., NOD) mouse, streptozotocin-induced diabetic rat or mouse, bio-breeding (i.e., BB) rat, and Chinese hamster. Type 2 diabetes models include the obese *ob/ob* mouse (leptin receptor deficient), *db/db* mouse (a point mutation in the leptin receptor gene), NONcNZO10 mouse, and Zucker *fa/fa* rats. The most common type 2 diabetic model (*db/db* mouse) has significant limitations in predicting humans outcomes because human type 2 diabetes does not involve leptin abnormalities and is polygenic. No animal model mimics the chronic problems that result in type 2 diabetic ulcers (Fang et al., 2010).

Pressure ulcer models

The primary cause of pressure ulcers is repeated ischemia-reperfusion injury caused by prolonged mechanical pressure, especially over a bony prominence. Pressure ulcers can be modeled in loose-skinned animals such as rats and mice by surgically implanting a metal plate under the skin (Figure 1), followed by intermittent and periodic compressions of the skin using an external magnet (Reid et al., 2004; Wassermann et al., 2009). Loose-skinned animals with little subcutaneous fat, mainly rats, are suitable for modeling aged human skin (Nguyen et al., 2008). Greyhound dogs have also been used because of their thin skin (Swaim et al., 1993). Pigs are better animals to model pressure ulcers of young humans because of their tight skin (Nguyen, 2008). A cast can be placed over a bony prominence in pigs to cause a reperfusion injury and friction on the skin surface (Swaim et al., 1997).

Ischemic wound models

The rabbit ear ulcer model has been extensively used to simulate ischemic wounds. Cutaneous ischemia is created by ear vessel ligation. Skin banding has been shown to create an ischemic model in guinea pigs (Constantine and Bolton, 1986). Bipedicle flap (surgically isolated area of skin with minimal continued blood supply) has been used to create ischemia on the dorsal skin of pigs (Figure 1). Molecular markers are used to validate the hypoxic state of tissues.

Biofilm-infected wound model

One characteristic of chronic human wounds is bacterial infection and biofilm, which impairs healing by inducing prolonged proinflammatory cytokines (Edwards and Harding,

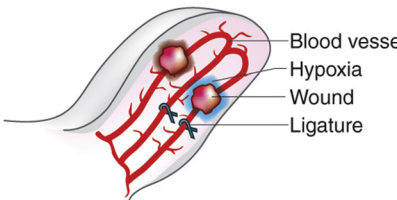


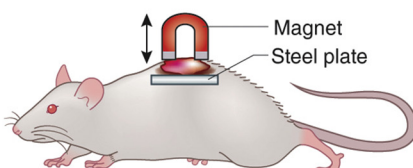
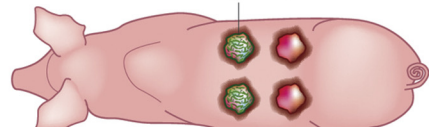
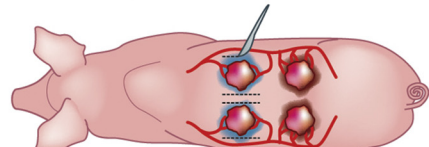

ANIMAL MODEL	FEATURES
a Rabbit ear Ischemic ulcer model  <p>Blood vessel Hypoxia Wound Ligature</p>	<p>Clinically relevant to ischemic ulcers</p> <p>Suturing of blood vessels generates an ischemic zone within which wounds can be made</p> <p>Benefits: accessible/suitable for pharmacological testing</p> <p>Drawbacks: does not fully replicate human hypoxic wounds and not genetically tractable</p>
b Diabetic mouse model 	<p>Clinically relevant to diabetic ulcers</p> <p>Diabetic mice are chemically or genetically induced</p> <p>Benefits: enable testing of pharmacological agents/multiple wounds per animal</p> <p>Drawbacks: mouse diabetes does not fully reflect human diabetic complications/variability between different diabetic models</p>
c Excision wound splinting model in mouse  <p>Ring splint</p>	<p>Clinically relevant to acute and chronic wounds</p> <p>Splinting ring tightly placed on the skin around the excisional wound</p> <p>Benefits: splinting minimizes contraction</p> <p>Drawbacks: anatomical differences between rodent and human skin; splinting materials may detach and move into the wound site</p>
d Rat pressure ulcer model  <p>Magnet Steel plate</p>	<p>Clinically relevant to pressure ulcers</p> <p>A steel plate is inserted beneath the dorsal skin</p> <p>A magnet is applied over a number of cycles to generate chronic skin wound</p> <p>Benefits: can vary in degree of blood perfusion to skin and thus grade of ulcer</p> <p>Drawbacks: anatomical differences between rodent and human skin</p>
e Pig infected wound model  <p>Infected wound</p>	<p>Clinically relevant to infected ulcers</p> <p>Wounds inoculated with bacteria that produce a biofilm</p> <p>Benefits: skin anatomically and physiologically similar to humans</p> <p>Drawbacks: expensive and not genetically tractable</p>
f Pig ischemic ulcer model 	<p>Clinically relevant to ischemic ulcers</p> <p>Surgical incisions sever blood flow to specific regions of skin, creating hypoxic zones</p> <p>Benefits: skin anatomically and physiologically similar to humans</p> <p>Drawbacks: expensive and not genetically tractable</p>
g Mouse tail full-thickness wound model 	<p>Clinically relevant to delayed wound healing</p> <p>Rectangular full-thickness excision on the dorsum of the tail</p> <p>Benefits: delayed healing (up to 21 days), minimal contraction, and can be used in wild-type animal.</p> <p>Drawbacks: anatomical differences between rodent and human skin</p>

Figure 1. Animal models of wound healing. (a–g) Examples of chronic skin wound animal models, their clinical relevance, benefits and drawbacks. (a) Rabbit ear ischemia model (profile view). (b) Chemically induced type 2 diabetic mouse model (dorsal view). (c) Excision wound splinting model in mouse (dorsal view). (d) Rat magnet ischemia-reperfusion model (profile view). (e) Pig wound infection model (dorsal view). This method is also applicable to rodents and rabbits. (f) Pig flap ischemia model (dorsal view). This method is also applicable to rodents and rabbits. (g) Mouse tail full-thickness wound model (dorsal view). This method is also applicable to wild-type, transgenic, and knockout mice. This work is partially derived from [Nunan et al. \(2014\)](#) used under CC BY.

Table 1. Features of different animal species used in modeling of wound healing				
Animal Species	Skin Type	Primary Healing Mechanism	Advantages	Limitations
Mouse	Loose skinned	Contraction	<ul style="list-style-type: none">• Small• Very common• Cost efficient• Easy to handle and maintain• Numerous transgenic, knockout, and gene-inducible lines readily available• Species-specific reagents widely available for many techniques such as immuno-histochemistry and flow cytometry• Broad knowledge base on mouse wound healing from years of extensive research• Mouse tail model enables the study of delayed healing in wild-type mice, which can then be used as controls in studies of mutant strains	<ul style="list-style-type: none">• Loose skin and very high hair density do not reflect the architecture of human skin• In the absence of outside intervention (i.e., splinting), wounds heal primarily via contraction, obviating the need for a robust proliferative phase of wound healing• Use of splinting to avoid contraction introduces foreign material to the wound site• Partial-thickness wounds can be difficult to make because of thinness of skin• Consistently poor translational efficacy of therapeutics in humans• Mouse genomic, immune, and inflammatory responses differ significantly from humans' after injury
Rat	Loose skinned	Contraction	<ul style="list-style-type: none">• Small• Common• Cost efficient• Easy to handle and maintain• Bigger than mice, which allows for larger or more numerous wounds per animal• Broad knowledge base on rat wound healing from years of extensive research	<ul style="list-style-type: none">• Loose skin and high hair density do not reflect the architecture of human skin• Heal primarily via contraction, thus minimizing the relevance of re-epithelization and granulation unless splinting technique is used• Use of splinting to avoid contraction introduces foreign material to the wound site• Less genetically tractable than mice• Relative paucity of species-specific reagents compared with mice

(continued)

2004; James et al., 2008). Wound-healing kinetics in the presence of biofilm have been studied in several animal models (Gurjala et al., 2011). After wounding a rodent, rabbit, or pig, a bacterial suspension of *Pseudomonas aeruginosa* or *Streptococcus aureus* can be applied to the surface of the wound. Bacterial concentration is adjusted according to pathogenicity, virulence, and the extent of the immune response of the host (Robson, 1997). An occlusive dressing should be used to prevent cross-contamination and provide optimal conditions for bacterial growth. The rabbit ear can be

used to combine a biofilm model with ischemia, increasing its clinical relevance (Gurjala, 2011). The rabbit ear model has been used to study the efficacy of traditional wound care in the presence of a *P. aeruginosa* biofilm (Seth et al., 2012).

CHOICE OF ANIMAL SPECIES
Several factors should be considered when choosing an animal species for wound experiments (Table 1). These include cost, availability, ease of handling, investigator familiarity, and similarity to humans. The use of small animals has a cost

Table 1. Continued

Animal Species	Skin Type	Primary Healing Mechanism	Advantages	Limitations
Rabbit	Loose skinned	Contraction	<ul style="list-style-type: none"> • Relatively inexpensive • Rapid breeding with prodigious offspring • Rabbit ear model overcomes wound contraction • Maybe well-suited to testing potential therapeutics, because rabbit and human skin respond similarly to aging, delayed healing, and various topical drugs • Can create several wounds in the same ear • Contralateral ear can be used as a control • Larger-caliber vessels make ischemic ligation easier • Rabbit ear model can be adapted for study of hypertrophic scarring 	<ul style="list-style-type: none"> • Limited genetic tractability • Paucity of species-specific reagents
Guinea pig	Loose skinned	Contraction	<ul style="list-style-type: none"> • Relatively small and cheap • Unable to produce endogenous vitamin C, so dietary deficiency allows study of the role of collagen in wound healing 	<ul style="list-style-type: none"> • Not commonly used today • Variable pregnancy rates, small and variable litter size, and relatively long gestational time (60–70 days) • Lack of transgenic methods and a limited number of strains
Pig	Tight skinned	Partial-thickness wound heals with re-epithelialization and granulation. Full-thickness wound heals with contraction.	<ul style="list-style-type: none"> • Large size allows for larger and more numerous wounds • Skin architecture, hair density, and physiology of wound healing most closely resemble what is seen in humans • Very relevant for preclinical studies looking at interventions 	<ul style="list-style-type: none"> • Expensive to maintain • Administration of anesthesia is more difficult and requires a skilled veterinarian • All surgical procedures generally require greater skill and expertise • Long gestational times • Poor genetic tractability and few transgenic lines available • Not practical for most research facilities • Dermis of larger, older animals is often significantly thicker than that of humans • Less vascular dermis and lack of eccrine sweat glands over almost all body surfaces are notable differences from human skin

(continued)

Table 1. Continued				
Animal Species	Skin Type	Primary Healing Mechanism	Advantages	Limitations
Zebrafish	Not applicable	Re-epithelialization and granulation	<ul style="list-style-type: none">• Small• Low cost• Greater genetic tractability• Healing phases are discrete and uncoupled from each other, allowing isolated study of a particular process (i.e., epithelialization)• Investigation of regenerative healing	<ul style="list-style-type: none">• Relatively underdeveloped model• Limited number of validated zebrafish reagents such as antibodies and cell lines are available to the research community

advantage. There are, however, several limitations, including limits to wound size, skin thinness relative to humans, follicular pattern, and hair growth cycle that differs from humans (Table 2). Wounds in areas with higher hair density heal faster than those in less hairy or nonhairy areas (Ansell et al., 2011).

Mouse

Mice are cost effective and amenable to genetic manipulation, which allows for mechanistic studies. Full-thickness surgical incisions and excisions performed on mouse dorsal skin are the most popular wound models. Dorsal sites tend to be quite useful in keeping the animal from reaching and manipulating the wound. For preclinical studies of therapeutics, each mouse can act as its own internal control because each animal can be given two wounds, enabling the application of both the treatment and control on the same mouse. However, using mice to simulate human wound closure has significant limitations. Wound healing in mice is fundamentally different from that in humans in that it is dominated by myofibroblast-mediated contraction. This difference is in part due to an extensive subcutaneous striated muscle layer called the panniculus carnosus that is mostly absent in humans. In mice, this muscle layer allows the skin to move independently of the deeper tissues; hence, it is called “loose skin.” A splinting technique is used to minimize contraction (Galiano et al., 2004; Wang et al., 2013) and to allow healing through granulation and re-epithelialization, similar to humans. Mouse skin in males is up to 40% stronger than in females because of a thicker dermal layer. By contrast, females have thicker epidermal and hypodermal layers (Wong et al., 2011).

Wound healing is significantly accelerated when mice were wounded in the late anagen compared with the catagen or telogen hair cycle stages (Ansell, 2011). To minimize the impact of hair follicles on wound healing, wounding must be created during telogen or early exogen, the resting phases of the hair cycle. One alternative is to use outbred hairless mice (*Hr* gene mutation).

Transgenic mice. Transgenic and knockout mouse models have been used to study the impact of a single gene in wound healing. IL-6–knockout mice have shown significantly delayed wound healing compared with wild-type mice

(Gallucci et al., 2000). Although genetically modified mice have tremendous potential for revealing the molecular pathways behind wound repair processes, overall, their utility is complicated by compensatory changes in gene expression and unanticipated effects, so that many gene knockouts have not given the predicted effects, and a great deal of effort goes into defining the molecular pathways involved in the phenotype (Fang and Mustoe, 2008).

Mouse tail. Ideally, one would like to have the option to model a chronic wound in wild-type animals. Traditionally, genetically modified strains, such as the diabetic *db/db* mouse, have been used to model impaired healing (Beer et al., 1997). Thus, the mouse tail model was developed to recapitulate delayed wound closure in the wild-type animal (Falanga et al., 2004). A rectangular (0.3 × 1.0 cm) full-thickness excision is made on the dorsal aspect of the tail, 1 cm distal to the body of the mouse (Figure 2). The excised skin exposes the underlying fascia, leaving a rectangular full-thickness defect. Compared with back dorsal wounds, which heal within a few days, the tail wounds require up to 21 days for full resurfacing, an expanded timeframe to test hypotheses and therapies. Because tail hair remains short, the wounds can be followed sequentially and measured clinically without killing the animals. Wild-type, transgenic, and knockout mice can be used.

Rat

Similar to mice, rats have loose skin and therefore heal predominantly by contraction. Healing by contraction is more rapid than re-epithelialization because new tissue is not formed. Unlike humans, mice and rats do not create hypertrophic scars or keloids. The collagen produced in their wounds comes from subcutaneous panniculus carnosus muscles (Cohen et al., 1979). Several wound models have used rats because of their size, wide availability, and tractable nature. Although mice may translate into lower maintenance budgets, rats provide a larger area of skin for wound studies. Male Sprague Dawley rats in the 250–300-gram weight range are the preferred strain. Male rats generally cost less than females of the same size (Dorsett-Martin, 2004).

An ischemic, H-shaped, double flap model in rats’ dorsum was developed for studying the influence of different factors on flap survival (Quirinia et al., 1992). However, this model

Table 2. Characteristics of human and animal skin: mean thickness of skin layers and hair density in animal species used in wound experiments

Species	Site	SC		VE		D		Hair Density, hairs/ cm ²	Healing Time Course, days	Source
		µm	SD/SE*	µm	SD/SE*	µm	SD			
Mouse	Dorsum	9	—	29	—	662	—	658 (thick)	Closes in <5 days because of contraction of skin	Monteiro-Riviere et al. (1990)
Mouse	Buttock, ear, shoulder, back, abdomen (paraffin)	3.38	±0.30*	11.50	±1.24*	—	—			
Mouse	Buttock, ear, shoulder, back, abdomen (frozen)	6.69	±0.96*	9.24	±0.96*	—	—			
Mouse	Back	~5	—	~21–22	—	~275–280		289 (thick)	Closes in <5 days because of contraction of skin	Ma et al. (2002)
Rat	Dorsum	18	—	32	—	2,040	—			Monteiro-Riviere et al. (1990)
Rat	Buttock, ear, shoulder, back, abdomen (paraffin)	4.04	±0.47*	15.34	±1.21*	—	—			
Rat	Buttock, ear, shoulder, back, abdomen (frozen)	9.91	±1.14*	10.70	±1.73*	—	—	80 (medium)	13–16, or longer depending on wound size	Oznurlu et al. (2009)
Rabbit	Lumbar dorsum	11.7	±3.6	20.6	±4.0	2,174.0	±486.7			Oznurlu et al. (2009)
Rabbit	Lumbar dorsum	9.5	±1.6	19.4	±4.8	1,719.3	±258.5			
Rabbit	Buttock, ear, shoulder, back, abdomen (paraffin)	6.89	±0.88*	13.83	±1.23*	—	—	11 (sparse)	12–14, or longer depending on wound size	Monteiro-Riviere et al. (1990)
Rabbit	Buttock, ear, shoulder, back, abdomen (frozen)	10.91	±1.48*	9.39	±1.25*	—	—			
Pig	Buttock, ear, shoulder, back, abdomen (paraffin)	12.85	±1.19*	53.17	±3.19*	—	—	11 (sparse)	7–14, or longer depending on wound size	Monteiro-Riviere et al. (1990)
Pig	Buttock, ear, shoulder, back, abdomen (frozen)	41.33	±3.73*	15.37	±1.51*	—	—			
Pig	Ear	17–28		60–85		1,440–2,210	(including H)	11 (sparse)	7–14, or longer depending on wound size	Jacobi et al. (2007)
Human	Abdomen	17	—	47	—	2,906	—			Monteiro-Riviere et al. (1990)
Human	—	10	—	50–120	—	2.28	—			
Human	Various sites	—	—	31–637	(including SC)	521–1,977	(E + D)			Lee and Hwang (2002)

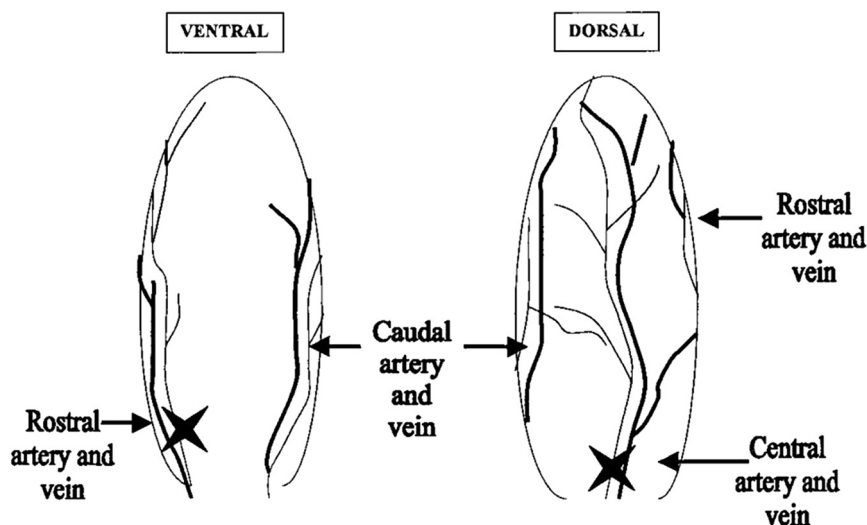
Abbreviations: D, dermis; E, epidermis; H, hypodermis or subcutaneous tissue; SC, stratum corneum; SD, standard deviation; SE, standard error; VE, viable epidermis.

Modified from [Wei et al. \(2017\)](#), used under CC BY.

*Denotes standard error (SE).

Figure 2. Ischemic rabbit ear model.

A circumferential incision is made at the base of the ear. The rostral and central arteries are ligated, leaving three main veins and the small caudal artery intact. Reprinted from Surgical Research, [Saulis A, Mustoe TA; 2001](#). p. 857-873. Models of Wound Healing in Growth Factor Studies. With permission from Elsevier.



has limitations. The rapidity with which the tissue returns to normal levels of perfusion prevents extended testing of potential therapeutic agents. Meanwhile, it is difficult to evaluate healing in incisional wounds, because breaking strength measurements reflect only one aspect of healing. An optimized ischemic flap model was established by creating full-thickness excisional wounds within a bipedicle dorsal skin flap in rats ([Gould et al., 2005](#)). In this model, modifications were made to the bipedicle flap model described initially by [Schwarz et al. \(1995\)](#). The two main modifications are (i) making the skin flap sufficiently narrow so that the blood supply is random and the wounds located in the midpoint of the flap are ischemic and (ii) inserting a silicone sheet beneath the skin flap, which prevents re-adherence and reperfusion of the flap from the underlying tissue. In this model, the panniculus carnosus muscle is removed from the wound bed by dissecting just above the muscle fascia. Wound contraction is limited (but not eliminated) by tacking the flap to the silicone sheet ([Gould, 2005](#)). The final product is a flap that does not develop necrosis yet remains ischemic for up to 2 weeks with markedly impaired healing.

Rabbit ear

Rabbit ear has been widely used as an ischemic wound model to study the effects of hypoxia on healing, as first described by [Ahn and Mustoe \(1990\)](#). The rabbit ear is vascularized by three main arteries ([Figure 3](#)). An ischemic zone is created by ligating two (rostral and central arteries) of the three arteries at the base of the ear through a circumferential incision, thus disrupting dermal arterial circulation while maintaining the veins. A 6-mm punch biopsy down through the cartilage will create a full-thickness wound that lacks a vascular base and has a very limited lateral vascular supply. Because the dermis of the rabbit ear is firmly attached to the cartilage, the avascular wound bed cannot close by contraction and, instead, heals via epithelialization and granulation tissue formation. However, the ischemia is reversible, and collateral circulation develops in about 14 days. The main advantage of this model is that rabbit ear provides a large surface area on which several

similar ulcers can be created in the same ear, and the contralateral ear can serve as a control. Furthermore, because of the splinting from ear cartilage, open wounds in the rabbit ear allow easy quantification of epithelialization as an independent variable from granulation tissue. Although theoretically a similar model could be applied to rodents, the technical aspects (surgical skills and magnification) have made this prohibitive.

The rabbit ear model has also been used to study the effects of various topical growth factors in promoting healing of chronic wounds ([Xia et al., 1999](#)). Although promising results were achieved with growth factor therapies in animal studies, human clinical trials have been disappointing. Nonetheless, some notable observations have been made that point to rabbit wounds behaving similarly to human wounds. These similarities include increased scarring with delayed epithelialization and less scarring with old age, topical steroids, and collagen synthesis inhibitors.

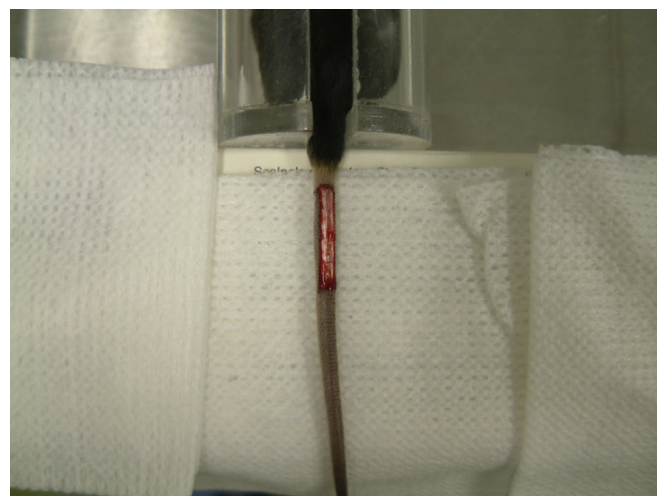


Figure 3. Mouse tail model. Gross appearance of a full-thickness wound on a mouse tail, immediately after wounding. The fascia is glistening white. Reprinted from [Falanga et al. \(2004\)](#) with permission from Wiley.

Pig

Pigs are standard models for wound healing because of the significant similarities to human skin (Montagna and Yun, 1964). Key similarities include epidermal and dermal thickness and related ratios (for weanling pigs), epidermal turnover time (around 30 days), pattern and structure of hair follicles, content and structure of dermal collagen and elastin, dermal metabolism, types of immune cells present, and biological response to growth factors. Perhaps most importantly, partial-thickness wounds in both pigs and humans heal mainly through re-epithelialization, not contraction. In contrast, circular full-thickness wounds heal significantly by contraction in pig models. Both percutaneous permeability and transdermal absorption in human skin is closer to those in pig skin than in other animal models (Bartek et al., 1972). Size of flaps, grafts, and dermal wounds have been standardized for comparison of therapeutic agents.

Pigs are substantially more expensive to purchase and maintain. Although human and pig skin are quite comparable in a number of facets, dissimilarities certainly exist. Pig skin has a higher pH, fatty subcutis, and predominantly apocrine sweat glands, with eccrine sweat glands confined only to specialized regions. Moreover, although microvascular anatomy is consistent between humans and pigs, skin vasculature, particularly of the dermis, is richer in human skin (Montagna and Yun, 1964). Weanling pigs have a dermis similar in thickness to humans, but larger animals have a much thicker and stiffer skin than humans. These differences are likely to have relevant implications for physiological studies.

The pig model is used to study a variety of cutaneous wounds including partial- and full-thickness excisional wounds, incisional wounds, laser-induced wounds, ischemic wounds, and second degree burns (Seaton et al., 2015). In pigs, limb denervation followed by casting has also been used to develop a model of pressure ulcers (Hyodo et al., 1995).

Guinea pig

Studies of the effects of vitamin C deficiency on wound healing are generally performed in the guinea pig because, like human beings, guinea pigs require vitamin C from dietary sources (Bartlett et al., 1942). The vitamin C-deficient ("scorbutic") guinea pig was used throughout the early to mid-20th century to investigate the role of collagen in wound healing (Abercrombie et al., 1956). Vitamin C is essential for collagen synthesis. Most other animals, including the pig, can synthesize their own vitamin C and thus do not make good models to study the effects of dietary vitamin C deficiency on wound healing.

Zebrafish

Zebrafish can regenerate many tissues and organs. A full-thickness wound model can be quickly and reproducibly created on the flank of adult zebrafish (Richardson et al., 2013). Wounds show rapid re-epithelialization (within hours), independent of coagulation and inflammation. Furthermore, a granulation-like tissue is formed and later cleared, resulting in minimal scar formation. Unlike the overlapping phases of wound healing in mammals, healing processes occur

MULTIPLE CHOICE QUESTIONS

- Which of the following animal species heal predominantly by contraction?
 - Humans
 - Pigs
 - Mice and rats
 - Zebrafish
- The mouse tail model has the following features except which of the following?
 - Rapid healing capacity
 - Can be used to study scarring
 - Offers longer duration of wound closure
 - Contraction is minimal
- Which of the following animal species is most relevant to partial-thickness wound modeling?
 - Pig
 - Greyhound
 - Rabbit
 - Guinea pig
- To choose an optimal animal model, one must take into consideration the following factors:
 - Size
 - Cost
 - Reproducibility
 - All of the above
- Which of the following adult animals exhibits scar-free skin regeneration?
 - Mouse
 - Rat
 - Pig
 - Zebrafish

See online version of this article for a detailed explanation of correct answers.

sequentially in zebrafish, allowing for better identification of direct and indirect effects caused by chemical or genetic manipulation. Furthermore, it provides an opportunity to perform high-throughput small-molecule drug screens (Richardson et al., 2016). The zebrafish model has been used to study the role of inflammation in wound healing (Hoodless et al., 2016).

CONCLUSION

Animal models provide invaluable information that can be correlated with human wound healing. When it comes to interpretation and implementation, one must not fail to recognize differences in each animal model. The investigator must assess the merits and limitations of each model according to the experimental objectives. Creating an animal model that reflects the complexity and heterogeneity of

chronic wounds in humans may be an unattainable goal because they are an outcome of multifactorial process that is influenced by both intrinsic and extrinsic factors such as impaired circulation, infection, chronic inflammation, poor nutrition, aging, limited physical activity, and chronic disease, among others. Useful models are designed such that these impairments are comparable, thus permitting a higher degree of validity. Given the ongoing advances in genetic manipulation of mice and other animal species, new, more useful models of the wound repair will eventually emerge.

CONFLICT OF INTEREST

The authors state no conflict of interest.

SUPPLEMENTARY MATERIAL

Supplementary material is linked to this paper. Teaching slides are available as supplementary material.

REFERENCES

- Abercrombie M, Flint MH, James DW. Wound contraction in relation to collagen formation in scorbutic guinea-pigs. *Journal of Embryology and Experimental Morphology* 1956;4:167–75.
- Ahn ST, Mustoe TA. Effects of ischemia on ulcer wound healing: a new model in the rabbit ear. *Ann Plast Surg* 1990;24:17–23.
- Ansell DM, Kloepper JE, Thomason HA, Paus R, Hardman MJ. Exploring the “hair growth–wound healing connection”: Anagen phase promotes wound re-epithelialization. *J Invest Dermatol* 2011;131:518–28.
- Bartek MJ, Labudde JA, Maibach HI. Skin permeability in vivo: comparison in rat, rabbit, pig and man. *J Invest Dermatol* 1972;58:114–23.
- Bartlett MK, Jones CM, Ryan AE. Vitamin C and wound healing: I. Experimental wounds in guinea pigs. *New Engl J Med* 1942;226:469–73.
- Beer H-D, Longaker MT, Werner S. Reduced expression of PDGF and PDGF receptors during impaired wound healing. *J Invest Dermatol* 1997;109:132–8.
- Cohen IK, Moore CD, Diegelmann RF. Onset and localization of collagen synthesis during wound healing in open rat skin wounds. *Proceedings of the Society for Experimental Biology and Medicine* 1979;160:458–62.
- Constantine B, Bolton L. A wound model for ischemic ulcers in the guinea pig. *Arch Dermatol Res* 1986;278:429–31.
- DiPietro LA, Burns AL. Wound healing: methods and protocols. New York: Springer-Verlag; 2003.
- Dorsett-Martin WA. Rat models of skin wound healing: a review. *Wound Repair Regen* 2004;12:591–9.
- Dunn L, Prosser HC, Tan JT, Vanags LZ, Ng MK, Bursill CA. Murine model of wound healing. *J Vis Exp* 2013;75:50265.
- Edwards R, Harding KG. Bacteria and wound healing. *Curr Opin Infect Dis* 2004;17:91–6.
- Elliot S, Wikramanayake TC, Jozic I, Tomic-Canic M. A modeling conundrum: murine models for cutaneous wound healing. *J Invest Dermatol* 2018;138:736–40.
- Eming SA, Martin P, Tomic-Canic M. Wound repair and regeneration: mechanisms, signaling, and translation. *Sci Transl Med* 2014;6(265):265sr266.
- Falanga V. Wound healing and its impairment in the diabetic foot. *Lancet* 2005;366(9498):1736–43.
- Falanga V, Schryer D, Cha J, Butmarc J, Carson P, Roberts AB, et al. Full-thickness wounding of the mouse tail as a model for delayed wound healing. *Wound Repair Regen* 2004;12:320–6.
- Fang RC, Kryger ZB, Buck I, Donald W, De La Garza M, Galiano RD, et al. Limitations of the db/db mouse in translational wound healing research: is the NONcNZO10 polygenic mouse model superior? *Wound Repair Regen* 2010;18:605–13.
- Fang RC, Mustoe TA. Animal models of wound healing: utility in transgenic mice. *J Biomater Sci Polym Ed* 2008;19:989–1005.
- Galiano RD, Michaels V, Dobryansky M, Levine JP, Gurtner GC. Quantitative and reproducible murine model of excisional wound healing. *Wound Repair Regen* 2004;12:485–92.
- Gallucci RM, Simeonova PP, Matheson JM, Kommineni C, Guriel JL, Sugawara T, et al. Impaired cutaneous wound healing in interleukin-6-deficient and immunosuppressed mice. *FASEB J* 2000;14:2525–31.
- Gould LJ, Leong M, Sonstein J, Wilson S. Optimization and validation of an ischemic wound model. *Wound Repair Regen* 2005;13:576–82.
- Gurjala AN, Geringer MR, Seth AK, Hong SJ, Smeltzer MS, Galiano RD, et al. Development of a novel, highly quantitative in vivo model for the study of biofilm-impaired cutaneous wound healing. *Wound Repair Regen* 2011;19:400–10.
- Helfman T, Ovington L, Falanga V. Occlusive dressings and wound healing. *Clin Dermatol* 1994;12:121–7.
- Hoodless LJ, Lucas CD, Duffin R, Denvir MA, Haslett C, Tucker CS, et al. Genetic and pharmacological inhibition of CDK9 drives neutrophil apoptosis to resolve inflammation in zebrafish in vivo. *Scientific Rep* 2016;6:36980.
- Hyodo A, Reger SI, Negami S, Kambic H, Reyes E, Browne EZ. Evaluation of a pressure sore model using monoplegic pigs. *Plast Reconstr Surg* 1995;96:421–8.
- Jacobi U, Kaiser M, Toll R, Mangelsdorf S, Audring H, Otberg N, et al. Porcine ear skin: an in vitro model for human skin. *Skin Res Technol* 2007;13:19–24.
- James GA, Swogger E, Wolcott R, Secor P, Sestrich J, Costerton JW, et al. Biofilms in chronic wounds. *Wound Repair Regen* 2008;16:37–44.
- Lee Y, Hwang K. Skin thickness of Korean adults. *Surg Radiol Anat* 2002;24(3–4):183–9.
- Ma T, Hara M, Sougrat R, Verbavatz J-M, Verkman A. Impaired stratum corneum hydration in mice lacking epidermal water channel aquaporin-3. *J Biol Chem* 2002;277:17147–53.
- Martin P. Wound healing—aiming for perfect skin regeneration. *Science* 1997;276(5309):75–81.
- Montagna W, Yun JS. The skin of the domestic pig. *J Invest Dermatol* 1964;42:11–21.
- Monteiro-Riviere NA, Bristol DG, Manning TO, Rogers RA, Riviere JE. Inter-species and interregional analysis of the comparative histologic thickness and laser Doppler blood flow measurements at five cutaneous sites in nine species. *J Invest Dermatol* 1990;95:582–6.
- Mustoe TA, O’Shaughnessy K, Kloeters O. Chronic wound pathogenesis and current treatment strategies: a unifying hypothesis. *Plast Reconstr Surg* 2006;117(7S):35S–41S.
- Nguyen P, Smith A-L, Reynolds K. A literature review of different pressure ulcer models from 1942–2005 and the development of an ideal animal model. *Australas Phys Eng Sci Med* 2008;31:223–5.
- Nunan R, Harding KG, Martin P. Clinical challenges of chronic wounds: searching for an optimal animal model to recapitulate their complexity. *Dis Model Mech* 2014;7:1205–13.
- Oznuurlu Y, Celik I, Sur E, Telatar T, Ozparlak H. Comparative skin histology of the white New Zealand and Angora rabbits. *J Ani Vet Adv* 2009;8:1694–701.
- Quirinia A, Jensen FT, Viidik A. Ischemia in wound healing I: design of a flap model—changes in blood flow. *Scand J Plast Reconstr Surg Hand Surg* 1992;26:21–8.
- Qvist MH, Hoeck U, Kreilgaard B, Madsen F, Frokjaer S. Evaluation of Göttingen minipig skin for transdermal in vitro permeation studies. *Eur J Pharm Sci* 2000;11:59–68.
- Reid RR, Sull AC, Mogford JE, Roy N, Mustoe TA. A novel murine model of cyclical cutaneous ischemia-reperfusion injury. *J Surg Res* 2004;116:172–80.
- Richardson R, Metzger M, Knyphausen P, Ramezani T, Slanchev K, Kraus C, et al. Re-epithelialization of cutaneous wounds in adult zebrafish combines mechanisms of wound closure in embryonic and adult mammals. *Development* 2016;143:2077–88.
- Richardson R, Slanchev K, Kraus C, Knyphausen P, Eming S, Hammerschmidt M. Adult zebrafish as a model system for cutaneous wound-healing research. *J Invest Dermatol* 2013;133:1655–65.
- Robson MC. Wound infection: a failure of wound healing caused by an imbalance of bacteria. *Surg Clin* 1997;77:637–50.
- Saulis A, Mustoe TA. Models of wound healing in growth factor studies. In: Wiley WS, Douglas WW, editors. *Surgical Research*. San Diego: Academic Press; 2001. p. 857–73.

- Schwarz DA, Lindblad WJ, Rees RS. Altered collagen metabolism and delayed healing in a novel model of ischemic wounds. *Wound Repair Regen* 1995;3:204–12.
- Seaton M, Hocking A, Gibran NS. Porcine models of cutaneous wound healing. *ILAR J* 2015;56:127–38.
- Seth AK, Geringer MR, Gurjala AN, Hong SJ, Galiano RD, Leung KP, et al. Treatment of *Pseudomonas aeruginosa* biofilm–infected wounds with clinical wound care strategies: a quantitative study using an in vivo rabbit ear model. *Plast Reconstr Surg* 2012;129:262e–74e.
- Swaim SF, Bradley DM, Vaughn DM, Powers RD, Hoffman CE. The greyhound dog as a model for studying pressure ulcers. *Decubitus* 1993;6:32–5, 38–40.
- Swaim SF, Hanson RR, Coates JR. Decubitus ulcers in animals. In: Parish LC, Witkowski JA, Crissey JT, editors. *The decubitus ulcer in clinical practice*. Berlin: Springer Berlin Heidelberg; 1997. p. 217–38.
- Velander P, Theopold C, Hirsch T, Bleiziffer O, Zuhaili B, Fossum M, et al. Impaired wound healing in an acute diabetic pig model and the effects of local hyperglycemia. *Wound Repair Regen* 2008;16:288–93.
- Wang X, Ge J, Tredget EE, Wu Y. The mouse excisional wound splinting model, including applications for stem cell transplantation. *Nat Protoc* 2013;8:302–9.
- Wassermann E, Van Griensven M, Gestaltner K, Oehlinger W, Schrei K, Redl H. A chronic pressure ulcer model in the nude mouse. *Wound Repair Regen* 2009;17:480–4.
- Wei JC, Edwards GA, Martin DJ, Huang H, Crichton ML, Kendall MA. Allometric scaling of skin thickness, elasticity, viscoelasticity to mass for micro-medical device translation: from mice, rats, rabbits, pigs to humans. *Sci Rep* 2017;7(1):15885.
- Wong VW, Sorkin M, Glotzbach JP, Longaker MT, Gurtner GC. Surgical approaches to create murine models of human wound healing. *BioMed Res Int* 2011;2011(1110-7243):969618.
- Xia YP, Zhao Y, Marcus J, Jimenez PA, Ruben SM, Moore PA, et al. Effects of keratinocyte growth factor-2 (KGF-2) on wound healing in an ischaemia-impaired rabbit ear model and on scar formation. *J Pathol* 1999;188:431–8.

RESEARCH TECHNIQUES MADE SIMPLE

DETAILED ANSWERS

1. Which of the following animal species heal predominantly by contraction:

Correct answer: c. Mice and rats

Mice and rats heal mainly by contraction due to an extensive subcutaneous striated muscle layer called the *panniculus carnosus* that is largely absent in humans. In mice and rats, this muscle layer allows the skin to move independently of the deeper muscles; hence, it is called “loose skin.” (Dunn et al., 2013).

2. The mouse tail model has the following features except:

Correct answer: a. Rapid healing capacity

The mouse-tail wound requires up to 21 days for full closure, which provides an expanded window of observation and identification of critical events involved in wound repair. Furthermore, the delayed healing occurring in this model could prove useful in testing potential therapeutic agents.

3. Which of the following animal species is most relevant to partial-thickness wound modeling?

Correct answer: a. Pig.

Pigs have been traditionally used in wound studies involving partial-thickness wounds because their skin is relatively similar to human skin in several ways such as the epidermal and dermal thickness (in weanling pigs), sparse hair coat,

epidermal turnover time, a well-differentiated papillary body, and large elastic tissue content. Partial thickness wound is difficult to perform on rodents due to their very thin skin. High hair density may also skew results due to higher rates of re-epithelization from hair. Pigs or hairless strains of mammals are better partial-thickness models.

4. To choose an optimal animal model, one must take into consideration the following factors:

Correct answer: d. All of the above

One must not fail to recognize differences in each animal model. The investigator must assess the merits and disadvantages of each model according to the experimental objectives. Due to anatomical and physiological differences among and within animal species, including humans, there is no single model that can suit all needs. Data generated from preclinical studies on wound repair may vary considerably depending on the animal model chosen.

5. Which of the following adult animals exhibits scar-free skin regeneration?

Correct answer: d. Zebrafish

Adult Zebrafish represent a valuable model for the study of wound regeneration. Zebrafish exhibit rapid reepithelization (within hours) and independently of inflammation, in response to full-thickness cutaneous wounding. Furthermore, a granulation-like tissue is formed and later largely cleared, resulting in minimal scar formation.